

## The Classic

### Congenital Club Foot: The Results of Treatment

Ignacio V. Ponseti MD, Eugene N. Smoley MD

Published online: 14 February 2009

---

**Abstract** This Classic article is a reprint of the original work by Ignacio V. Ponseti and Eugene N. Smoley, Congenital Club Foot: The Results of Treatment. An accompanying biographical sketch on Ignacio V. Ponseti, MD, is available at DOI [10.1007/s11999-009-0719-8](https://doi.org/10.1007/s11999-009-0719-8) and a second Classic article is available at [10.1007/s11999-009-0721-1](https://doi.org/10.1007/s11999-009-0721-1). This article is ©1963 by the Journal of Bone and Joint Surgery, Inc., and is reprinted with permission from

Ponseti IV, Smoley EN. Congenital Club Foot: The Results of Treatment. *J Bone Joint Surg Am.* 1963;45:261–344.

© The Association of Bone and Joint Surgeons 2009

---

Richard A. Brand MD ✉  
Clinical Orthopaedics and Related Research,  
1600 Spruce Street,  
Philadelphia, PA 19103, USA  
e-mail: dick.brand@clinorthop.org

---

Since 1948, a uniform system of treatment has been applied to all cases of congenital club foot on the Orthopedic Service of the State University of Iowa. Our aim has been to obtain a supple, well corrected foot in the shortest possible time. An end-result study of severe club-foot deformities in otherwise normal children treated initially in this department from 1948 to 1956, with a follow-up period from five to twelve years, is here presented.

Three hundred and twenty-two patients with club-foot deformity were treated during this period. The following were not included in this study: One hundred and forty-nine patients had been originally treated in other clinics and were referred to us for further correction. Ten patients had arthrogryposis; four had a complete or partial absence of the tibia; and eighteen had a myelomeningocele. The sacrum was absent in two and congenital constriction was present in the legs above the malleoli in two patients. In forty-six patients, the foot deformity was mild and was corrected by simple manipulations or the application of one to three plaster casts. Of the remaining ninety-one otherwise normal children with severe untreated club-foot deformities, twenty-four were lost to follow-up, usually at the end of the initial treatment.

We were able to evaluate the results of treatment in only sixty-seven patients with a total of ninety-four club feet. All these deformities were severe, although many variations in the degree of rigidity of the feet were present. The age of the patient at the onset of treatment ranged from one week to six months, and the average age was one month. Of the sixty-seven patients studied, ten were female and fifty-seven were male. The deformity was, therefore, almost six times as prevalent in male as in female children. Forty patients had only one foot deformed (60 per cent) and twenty-seven patients had both feet deformed (40 per cent). In the patients with unilateral involvement, the right foot was deformed in eighteen and the left foot in twenty-two cases. Anteroposterior and lateral roentgenograms and photographs of the feet of all patients were made at the onset of treatment and again at the time of the final examination.

#### Method of Treatment

We aimed at an early and full correction of all the components of the deformity by gentle manipulation and well

molded, thinly padded plaster casts which were changed every four to seven days. Anesthesia was never used. The plaster cast was applied in two sections, the first section extended from the toes to just below the knee and the second covered the knee and thigh. The knee was immobilized at a right angle while the leg was gently rotated outward to correct tibial torsion.

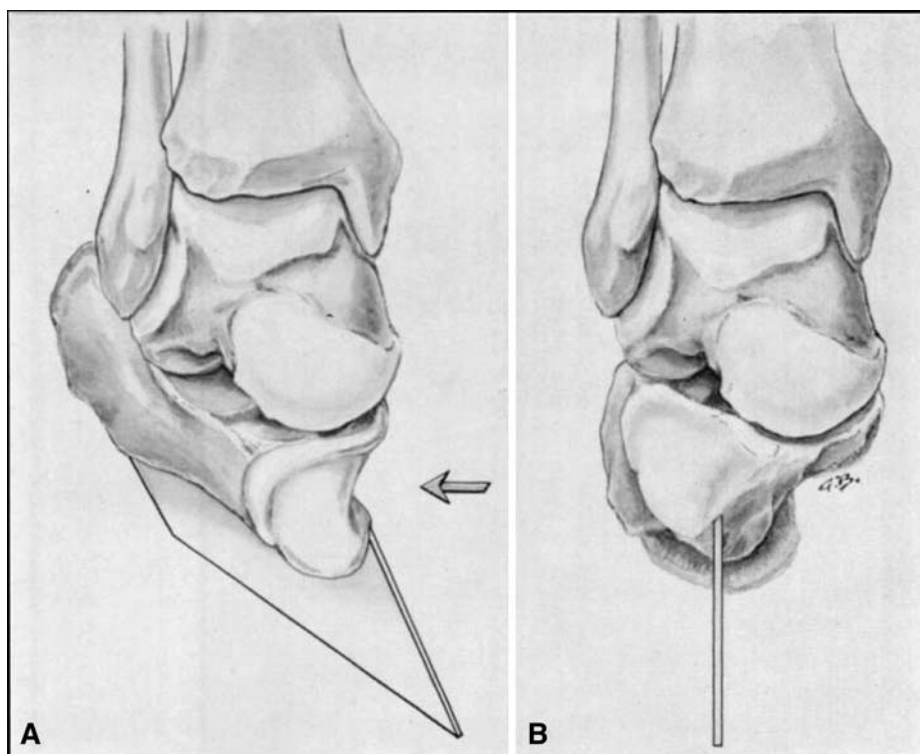
A clear understanding of the club-foot deformity is possible after identifying by palpation the position of the bones in the foot and their relationship to one another and to the leg. The foot is displaced and rotated medially beneath the talus. The head of the talus is palpable on the lateral aspect of the dorsum of the foot, owing to the inward and backward displacement of the navicular. The calcaneus is in severe equinus deformity with its anterior portion lying directly beneath the head of the talus. This displacement is responsible for the severe varus deformity of the heel (Fig. 1A–B). The cuboid is also displaced inward in front of the calcaneus. The cuneiforms are displaced downward and inward in front of the navicular. The medial displacements of the navicular, cuboid, cuneiforms, and metatarsals contribute in different degrees to the severe adduction deformity of the club foot. The varus deformity of the calcaneus and the adduction of the mid-tarsometatarsal bones together are responsible for the inversion. The fore part of the foot, although adducted and inverted, is not as severely inverted as the hind part. As a result, the front of the foot is somewhat pronated with respect to the back of

the foot, and this relationship causes the cavus deformity. The cavus deformity is thus produced by the slight downward displacement of the cuneiforms and by the fact that the first metatarsal is plantar flexed to a greater degree than the fifth metatarsal. The cavus deformity is sometimes erroneously designated as equinus of the fore part of the foot. Excessive plantar flexion of the anterior part of the foot occurs primarily on its inner aspect. The plantar flexion of the outer aspect of the front part of the foot may be normal, as evidenced by the fact that the calcaneus, cuboid, and fifth metatarsal are in a straight line, even though the club foot deformity is severe (Fig. 2A–F).

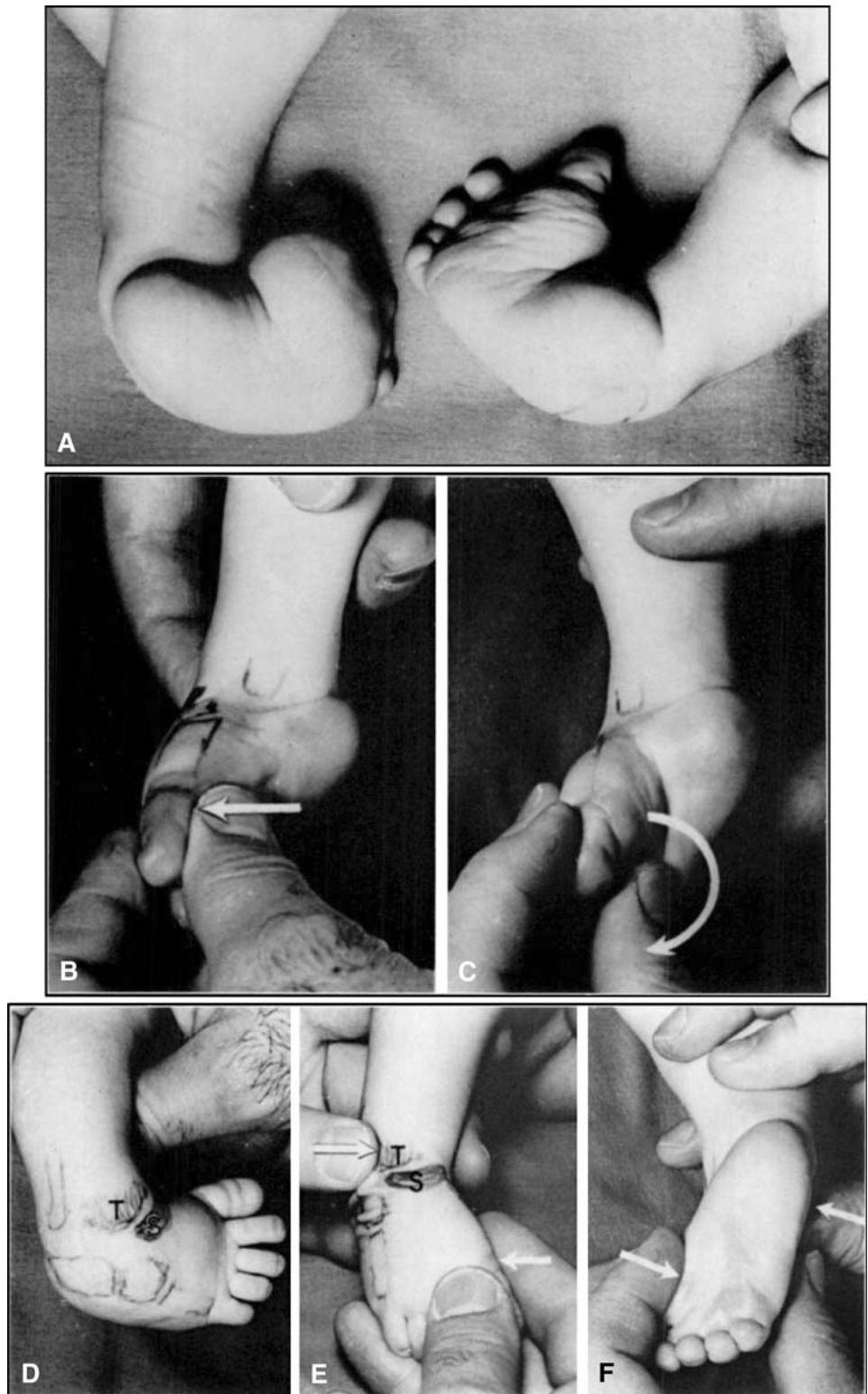
Brockman noted that in a club foot there is subluxation of the talocalcaneonavicular joint and alterations in position of the navicular and calcaneus with respect to the talus like those which occur in the normal foot when it is adducted, inverted, and plantar flexed, but they are exaggerated in degree. However, a normal foot cannot adopt a true club-foot position because even in the extreme degrees of plantar flexion and inversion, the fore part of the foot moves with the hind part, and a cavus deformity does not develop since there is no discrepancy in the degree of inversion of the front and back part of the foot.

The cavus deformity must be corrected with the first cast. Since the cavus deformity is related to the pronation of the fore part of the foot with respect to the hind part, the cavus is corrected by placing the fore part of the foot in supination in proper alignment with the hind part. An

**Fig. 1A–B** (A) In club foot, the anterior portion of the calcaneus lies beneath the head of the talus. This position causes varus and some equinus deformity of the entire calcaneus. (B) Lateral displacement of the anterior portion of the calcaneus to its normal relationship with the talus will correct the heel varus deformity of the club foot.



**Fig. 2A–F** (A) Severe bilateral club-foot deformity in a six-week-old infant. The heel is in severe varus deformity. The fore part of the foot is adducted and inverted. The cavus deformity results from the slightly pronated position of the fore part of the foot in relation with the heel. (B) Manipulation to correct the cavus deformity. The fore part of the foot is slightly supinated to be placed in proper alignment with the hind part of the foot. (C) Wrong maneuver to correct the inversion. This maneuver increases the cavus deformity and fails to correct the varus deformity of the heel. (D) The outlines of the bones were drawn on the skin. The head of the talus (*T*) was palpable in the dorsolateral aspect of the foot in front of the ankle joint. The navicular (*S*) was displaced medially and its tuberosity was palpable just anterior to the medial malleolus. The first metatarsal is almost in a straight line with the cuboid and calcaneus. (E) and (F) Manipulation to correct the inversion: outward pressure is exerted on the first metatarsal and counter pressure on the lateral aspect of the head of the talus (*T*). When the navicular and cuboid and the entire fore part of the foot are displaced laterally in relation with the head of the talus, the anterior portion of the calcaneus follows; thus, the heel varus deformity is corrected. While the inversion is corrected the fore part of the foot should not be pronated to prevent recurrence of the cavus deformity.



attempt to correct the inversion of the foot by forcible pronation of the anterior part of the foot will increase the cavus deformity as the first metatarsal is further plantar flexed. This common maneuver is harmful because it

hinders greatly any correction of the club-foot deformity by increasing the pronation of the fore part of the foot and thus making it very difficult to mobilize the navicular and displace it laterally in relation to the head of the talus. The

navicular, cuneiforms, and metatarsals should be placed in straight alignment to form the lever arm needed for the correction of the inversion (Fig. 2B–C).

To correct the inversion of the foot, all of the foot distal to the talus must be made to rotate laterally underneath the talus which is fixed in the ankle mortise. A thumb placed on the lateral aspect of the head of the talus is used as a fulcrum while outward pressure is exerted on the first metatarsal and first cuneiform. During this manipulation an attempt is made to realign properly and simultaneously the calcaneocuboid, the talocalcaneonavicular, and the posterior talocalcaneal joints. When the navicular and cuboid are displaced laterally, the anterior portion of the calcaneus will be displaced outward and upward from its initial position underneath the head of the talus, and thus the varus deformity of the heel will be corrected (Fig. 1A–B). Care is taken not to pronate the fore part of the foot during this manipulation to prevent recurrence of the cavus deformity (Fig. 2E). The manipulations should be gentle and followed by the application of a well molded thinly padded light plaster cast. Four to five plaster-cast changes are usually sufficient to correct the inversion of the foot.

The equinus deformity is corrected next by dorsiflexing the foot with the heel in a neutral or slight valgus position. This is the most difficult deformity to correct because of the great shortening of the tendo achillis which resists stretching. Two to three casts are often applied after manipulations in an attempt to correct equinus deformity. If it then becomes evident that many more casts will be necessary for a complete correction, a simple subcutaneous tenotomy of the tendo achillis is performed with the patient under general anesthesia. A toe-to-groin cast with the foot in maximum dorsiflexion and the knee at a right angle is then applied for three weeks. The equinus deformity is thus immediately corrected, obviating a rocker-bottom deformity which often results from prolonged forceful manipulation. When the plaster cast is removed three weeks later, the defect in the tendon is healed. The scar in the tendon after this procedure is minimum, as observed in several instances where a tendo achillis lengthening was performed several years later to correct a recurrence.

Medial tibial torsion of variable degree is present in most patients with club feet and is a tenacious deformity if below-the-knee casts are used during treatment. Tibial torsion can be gradually corrected when toe-to-groin casts are applied with the knee in 90 degrees of flexion. To do this, the leg portion of the cast which includes the foot is held in slight outward rotation while the thigh portion hardens.

From five to ten (average 7.6) plaster casts worn for periods of from five to twelve weeks (average 9.5 weeks) were necessary for the correction of all the club-foot components in our cases. A subcutaneous section of the

tendo achillis was done in seventy-four of the ninety-four feet. To prevent recurrences of the deformity, Denis Browne splints with high-top shoes with well molded heels were applied after the plaster-cast treatment. These splints were left on full time for an average period of three months and at night for an average of twenty-one and a half months more (ranging from ten to thirty months).<sup>1</sup> Ordinary high-top shoes were used for walking. No sole wedges were prescribed.

#### First Recurrence

The deformity recurred in fifty-three feet (56 per cent) (Table 1) at ages ranging from ten months to five years, with an average of two and one-half years. Some authors [1] stated that recurrences only occur when the club-foot deformity is not completely corrected at the initial treatment. However, when we reviewed the roentgenograms made at the end of the primary treatment, we found that the relationship of the talus to the calcaneus had not been completely corrected in only five cases. The causes for the recurrences are difficult to determine. In the forty-one feet permanently corrected with the first treatment the deformity tended to be less rigid, the leg muscles better developed, and the length of Denis Browne splint treatment longer than in the feet with recurrent deformities. Also, the family of patients without recurrence tended to be more cooperative. About half of the recurrences occurred from two to four months after the Denis Browne splints were discarded, usually on the family's own initiative; the recurrences could be blamed on the neglect of follow-up treatment with these splints. In other patients the recurrence was associated with a severe initial deformity and apparently poorly developed leg muscles; these recurrences seemed to be related to the severity of the primary aberration which caused the deformity.

In six patients the recurrence was treated with the Denis Browne splint worn at night and during napping hours. In forty-seven patients, the recurrence was more severe and was treated with manipulation and toe-to-groin plaster casts changed each week. The cast treatment lasted from three to twelve weeks (an average of 6.4 weeks). In the majority of recurrences, the equinus deformity was mild and responded to conservative treatment. Of the seventy-four feet treated with heel-cord section at primary treatment three required further surgery. The tendo achillis was sectioned subcutaneously again in one patient and was lengthened through a short medial longitudinal skin incision in the other two patients. The equinus deformity was resistant in seven feet not surgically treated initially. The

<sup>1</sup> For the past four years, Denis Browne splints have been worn at night until the age of three to five years.

**Table 1.** Treatment of recurrences

	First	Second	Third	Fourth
No. of patients	37	12	7	1
No. of feet	53	17	9	1
Average age (years)	2½	3	4½	7
Treatment	No. of feet	No. of feet	No. of feet	No. of feet
Plaster casts	47 (6.4 wks.)	17 (8 wks.)	9 (7 wks.)	1 (6 wks.)
Denis Browne splints	6 (11 mos.)			
Subcutaneous section, tendo achillis	5*	4**	1*	
Tendo achillis lengthening	5**	1	1*	
Anterior tibial transfer	27	5	6	1
Recession, extensor hallucis longus	3	1		1
Recession, extensor digitorum longus		1		
Subcutaneous plantar fasciotomy	1	1		1
Medial release		1	2	
Lisfranc capsulotomy	1			

\* One foot had subcutaneous tendo achillis tenotomy with the initial treatment.

\*\* Two feet had subcutaneous tendo achillis tenotomy with the initial treatment.

tendo achillis was sectioned subcutaneously in four of these and lengthened in the other three. A subcutaneous section is preferred in patients under one year of age and tendo achillis lengthening in the older patients. In many of the recurrences, the varus deformity of the heel was more resistant to conservative treatment than the equinus deformity. A transfer of the anterior tibial tendon to the third cuneiform was done in twenty-seven feet in which there was a tendency for this muscle to supinate the foot strongly after the correction [3]. The tendon was transferred to the third cuneiform in nineteen feet and to the cuboid in eight. The tendon was attached to the bone through a drill hole using a Bunnell pull-out suture in twenty-one feet and a silk suture and osteoperiosteal flap in six feet. Two skin incisions were made, one along the distal one or one and one-half inches of the anterior tibial tendon, the other shorter incision on the dorsum of the foot at the level of the third cuneiform. The tendon was transferred to its new attachment without changing its position underneath the ankle retinaculum. The foot was immobilized in a toe-to-groin plaster cast for four weeks. An over-correction of the club-foot deformity after this procedure was not observed in this series. In three feet in addition to the anterior tibial transfer the extensor hallucis longus was recessed to the neck of the first metatarsal after suturing its distal stump to the tendon of the short extensor of the big toe. The recession of the extensor hallucis longus was done in cases with severe plantar flexion of the first metatarsal and hyperextension of the first metatarsophalangeal joint. In one foot with severe cavus deformity, a subcutaneous plantar fasciotomy was performed. In another, a Lisfranc

capsulotomy was done to correct a severe metatarsus adductus [4].

#### Second Recurrence

A second recurrence was observed in seventeen feet (18 per cent) at ages ranging from fourteen months to five years, the average being three years. In five of these seventeen feet the initial club-foot deformity was very rigid and the leg muscles were atrophic. Four other feet were short and stubby and hence difficult to treat. The first recurrence in these four feet and the first recurrence in three other feet with deformities of average severity had been incompletely corrected by the application of only two to four plaster casts. In the five remaining feet the second recurrence was observed shortly after the Denis Browne splint was discarded prematurely.

The second recurrence was treated with reapplication of toe-to-groin plaster casts changed every one to two weeks for periods ranging from four to twelve weeks (average, eight weeks). This was followed by a subcutaneous section of the tendo achillis in four feet, a lengthening of the tendo achillis in one foot, and a transfer of the anterior tibial to the third cuneiform in five feet. In one foot, the extensor hallucis longus was recessed to the neck of the first metatarsal, all the tendons of the extensor digitorum longus were recessed to the third cuneiform, and a subcutaneous plantar fasciotomy was done to relieve the cavus deformity. A medial release operation was necessary in another foot with a severe recurrence which had been treated previously by plaster-cast applications and transfer of the anterior tibial tendon.

### Third Recurrence

The deformity recurred for the third time in nine feet (10 per cent) at an age ranging from three to eight years (average, four and a half years). In five of these feet, the recurrence was mild and was apparently caused by the strong supinatory action of the anterior tibial muscle. These recurrences were permanently corrected by lateral transfer of the anterior tibial tendon after the application of two or three plaster casts. The other four feet were somewhat rigid and the leg muscles were very atrophic. In one of these, a medial release operation, as well as a subcutaneous section of the tendo achillis, was necessary; in another, a medial release was combined with a transfer of the anterior tibial tendon to the third cuneiform; in the third, a tendo achillis lengthening was performed; and in the fourth treatment consisted in five plaster-cast changes which were followed by a recurrence of the deformity.

### Fourth Recurrence

The last foot, just mentioned, was the only fourth recurrence observed (1 per cent). Treatment consisted in the application of one plaster cast followed by a subcutaneous plantar fasciotomy, a transfer of the anterior tibial tendon to the third cuneiform, and a recession of the extensor hallucis longus to the neck of the first metatarsal.

## Results

The correction obtained in each of the components of the club-foot deformity was evaluated clinically and roentgenographically. Both evaluations correlated closely with respect to ankle dorsiflexion, heel varus, and adduction of the fore part of the foot. Therefore only the clinical measurements of these components are charted (Table 2). All the clinical measurements were performed by the senior author for the sake of uniformity.

On the anteroposterior roentgenograms, the degree of heel varus deformity was estimated by measuring the angle formed by the long axis of the talus and the calcaneus. A 30-degree angle was considered normal and was classified as 0 degree of heel varus deformity. Thus a measured talocalcaneal angle of 20 degrees corresponded to

**Fig. 3A–L** Part I. (A–D) Anteroposterior and lateral roentgenograms of the feet of a six-week-old baby boy with severe congenital club feet. In the anteroposterior roentgenograms, the talus and calcaneus are superimposed and their axes coincide indicating a severe heel varus deformity. The angle between the axis of the calcaneus and that of the fifth metatarsal (adduction of the fore part of the foot) measures 74 degrees. In the lateral views, the angle formed by the long axis of the calcaneus and that of the first metatarsal (cavus) measures 86 degrees. The calcaneus is in severe equinus and the talus is subluxated forward in relation with the tibial mortise. Treatment consisted in manipulation and application of five plaster casts for the correction of the cavus, the adduction, and the heel varus deformities. This took a total period of one month. A bilateral tenotomy of the tendo achillis was then performed followed by a plaster cast applied for three weeks. (E–H) Anteroposterior and lateral roentgenograms made after removal of the last plaster cast, seven weeks after onset of treatment. In the anteroposterior roentgenograms the angle between the long axis of the talus and that of the calcaneus measures 33 degrees, indicating correction of the heel varus deformity, and the angle between the calcaneus and the fifth metatarsal measures 13 degrees, indicating correction of the adduction of the fore part of the foot. In the lateral roentgenograms the equinus deformity appears corrected and the angle between the long axis of the calcaneus and that of the fifth metatarsal measures 7 degrees, indicating correction of the cavus deformity. Denis Browne splints on shoes were worn full time for ten months and at night until four and one-half years of age. Part II. (I–L) Anteroposterior and lateral roentgenograms made when the boy was seven years old. A good result was obtained in the right foot (I and K) and an acceptable result in the left (J and L). In the anteroposterior roentgenograms, the angle between the long axis of the calcaneus and that of the talus measures 28 degrees on the right and 22 degrees on the left, indicating correction of the heel varus deformity on the right and incomplete correction on the left. The angle between the calcaneus and fifth metatarsal measures —7 degrees on the right and 0 degree on the left, indicating correction of the adduction of the fore part of both feet. In the lateral roentgenograms the angle between the long axis of the calcaneus and that of the first metatarsal measures 32 degrees on the right and 24 degrees on the left, indicating correction of the cavus deformity in both feet.

10 degrees of heel varus deformity. The adduction of the fore part of the foot was also estimated on the anteroposterior roentgenograms by measuring the angle between the long axis of the calcaneus and that of the fifth metatarsal. On the lateral roentgenograms, the cavus deformity was estimated by measuring the angle between the long axis of the calcaneus and that of the first metatarsal (Fig. 3). The correction of the equinus deformity was estimated by measuring the degree of ankle dorsiflexion. The degree of tibial torsion was estimated clinically by having the patient seated on the edge of the examining table with the knees at 90 degrees of flexion and the feet in slight plantar flexion. In the normal foot, the head of the talus can be palpated in

**Table 2.** Results

Ankle dorsiflexion (Degrees)	Heel varus (Degrees)	Adduction of the fore part of the foot (Degrees)	Tibial torsion (Degrees)	Result
> 10	0	0–10	0	Good: 67 feet (71 per cent)
0–10	0–10	10–20	Moderate	Acceptable: 26 feet (28 per cent)
0	Over 10	Over 20	Severe	Poor: 1 foot (1 per cent)

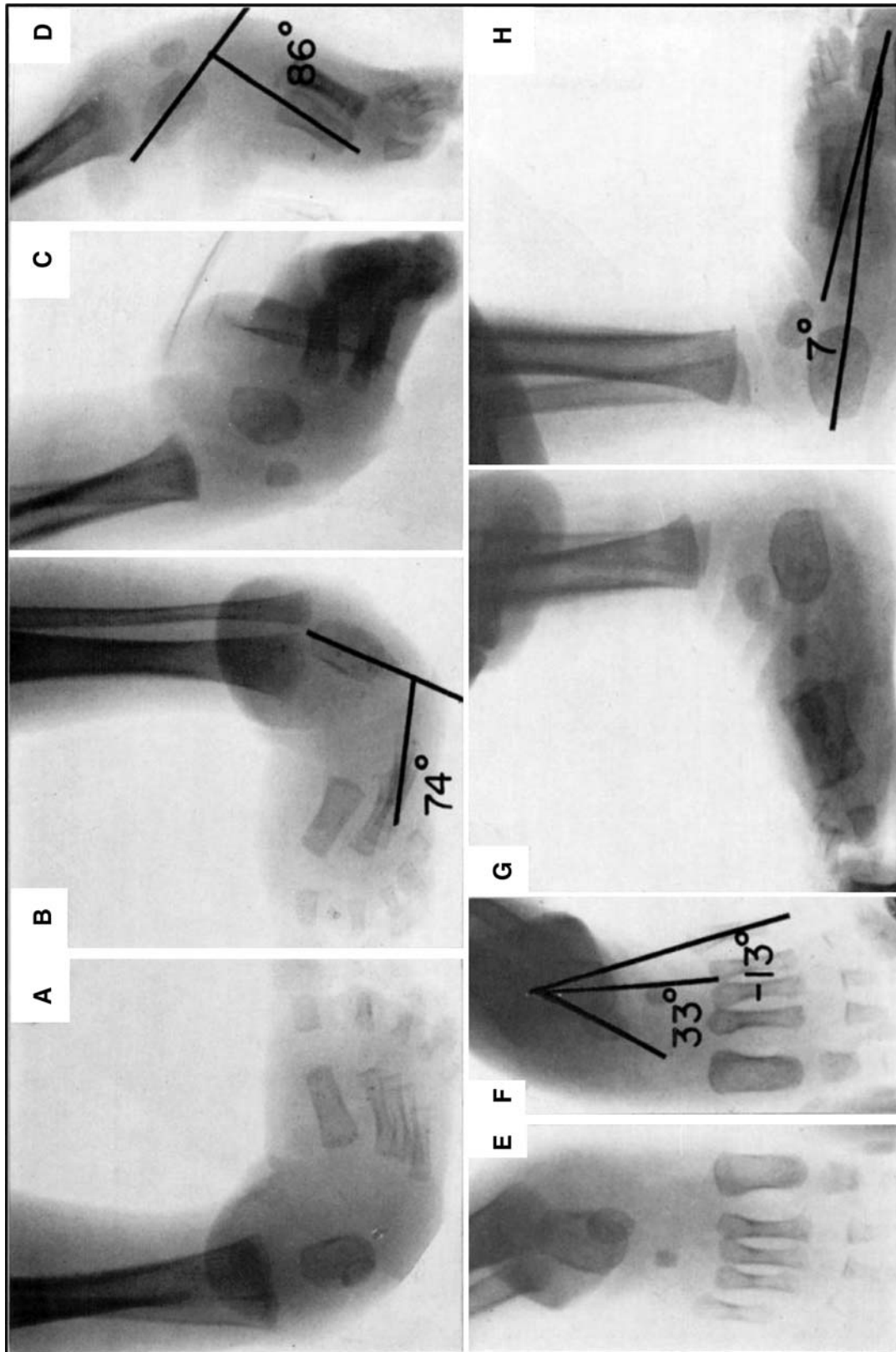


Fig. 3 Part I.

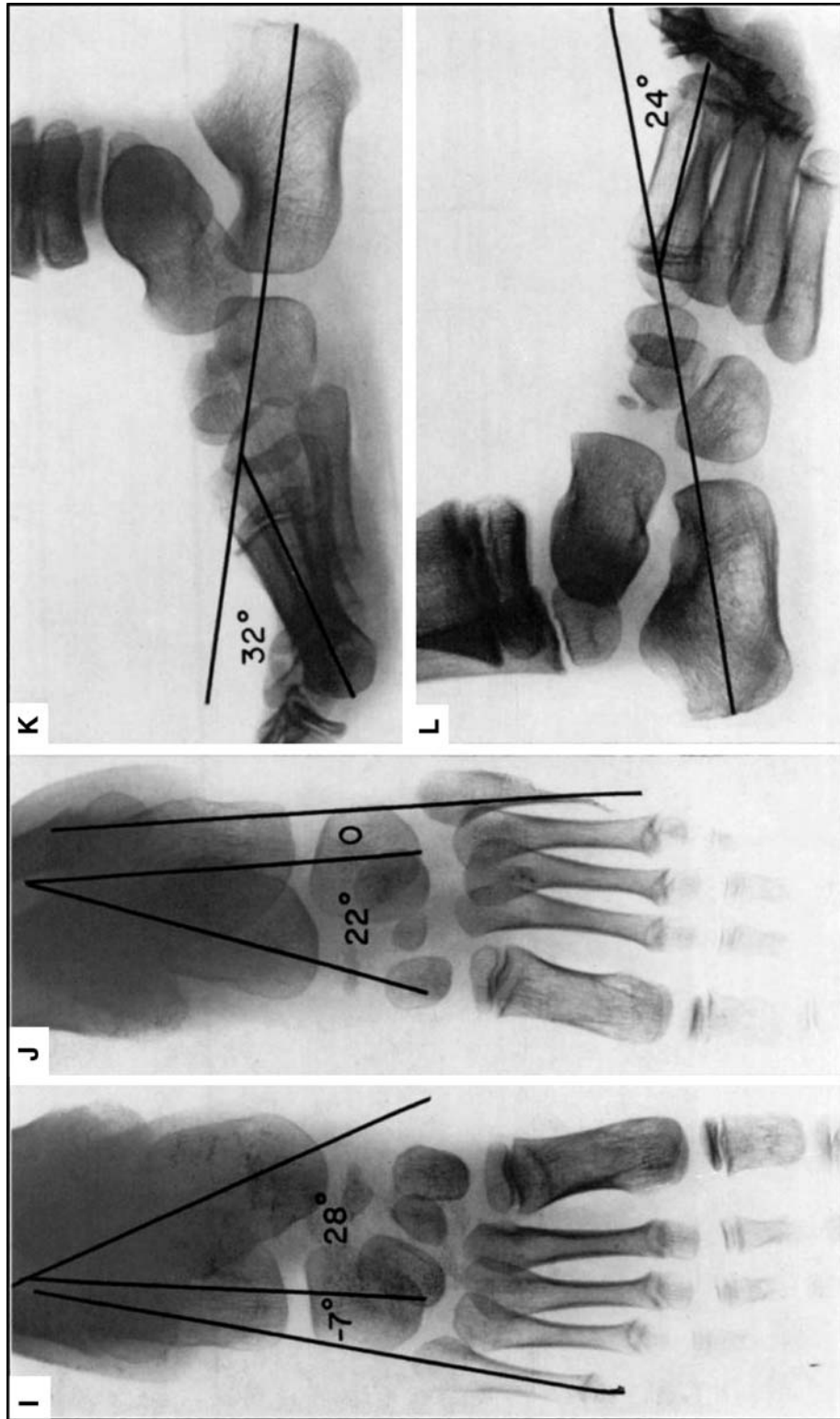


Fig. 3 Part II.



front of the ankle mortise in the same plane as the axis of the thigh. Medial or lateral tibial torsion is indicated by the orientation of the head of the talus in respect to the patella and axis of the thigh.

The cavus deformity was corrected in most feet by the first plaster-cast application. The recurrences of this deformity were usually mild and responded to manipulation and plaster-cast applications with upward pressure on the first metatarsal head. However, a subcutaneous plantar fasciotomy was necessary in three feet with severe cavus deformity. In two of the three feet, this operation was combined with recession of the extensor hallucis longus tendon to the neck of the first metatarsal. Recession of this tendon was done in three other feet with severe plantar flexion of the first metatarsal. All these operations were successful, and in the final examination the cavus deformity was corrected in all cases.

The heel varus deformity was completely corrected in seventy feet (74 per cent). A slight degree of heel varus deformity of less than 10 degrees persisted in twenty-four feet (26 per cent). The heel varus deformity was corrected after the initial treatment in all feet but it recurred in fifty-two. Anterior tibial transfer was done after plaster-cast correction in thirty-nine of these feet. The operation was successful in thirty feet but from 1 to 10 degrees of heel varus deformity persisted in nine feet. In six of these feet, the tendon pulled loose from its insertion (in three the wire broke and in the other three the silk stitches apparently came loose). In three feet the tendon was transferred to the third cuneiform and probably should have been transferred to the cuboid. The thirteen remaining recurrences had slight residual heel varus that did not require treatment.

Adduction of the fore part of the foot was completely corrected in seventy-two feet (77 per cent), was less than 20 degrees in twenty-one feet (22 per cent), and was severe in one foot. In one foot with severe adduction, the deformity was corrected by capsulotomy of the Lisfranc joint. Of the twenty-two feet with residual adduction, seven had an anterior tibial transfer and fifteen did not. It appears then that anterior tibial transfer may help to correct not only the heel varus deformity but also the adduction of the fore part of the foot.

Tibial torsion was completely corrected in seventy-eight feet (83 per cent). In fifteen feet (16 per cent) a moderate residual medial tibial torsion (if less than 10 degrees was observed, and in one there was tibial torsion of 20 degrees. In no instance was an osteotomy of the tibia performed.

Dorsiflexion of the ankle of more than 10 degrees above a right angle with the knee in extension was observed in seventy-five feet (80 per cent). In this group are included ten feet in which neither section nor lengthening of the tendo achillis was performed and sixty-five feet which had this tendon sectioned at the initial treatment. In eighteen

feet (19 per cent) dorsiflexion of the ankle was limited to from 0 to 10 degrees. Eight of these feet had the tendo achillis sectioned at the initial treatment. A second section of the tendon was done in four to treat a recurrence, and in three the tendon was lengthened. The other ten feet of this group had either a section or a lengthening of the tendo achillis at the time of the first or second recurrence. One foot in which the heel cord was sectioned at the initial treatment and sectioned again at the third recurrence had a 5-degree residual equinus deformity. Mild flattening of the superior articular surface of the talus was observed in the final roentgenograms of this last foot and in fourteen feet of the preceding group. The over-all rating of results is summarized in Table 2. Good results were obtained in 71 per cent of the feet (Figs. 4 and 5), acceptable in 28 per cent (Figs. 6 and 7), and poor in 1 per cent.

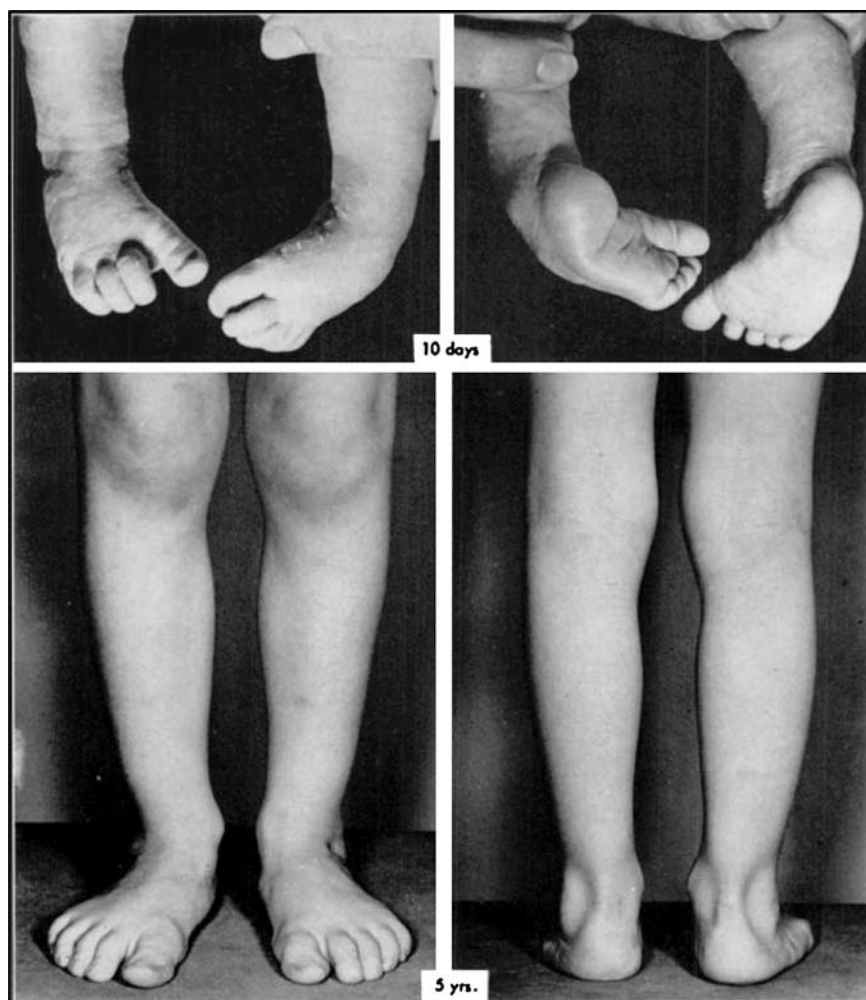
## Discussion

Although the treatment of a mild congenital club foot may be easy, the complete and permanent correction of a severe and rigid club foot is often difficult. In this study, we have been concerned with the severe cases only. The early months of life offer a golden opportunity for the correction of club feet since the skeleton, which is to a great extent cartilaginous, is little deformed, and the joint capsules, ligaments, tendons, and muscles can be stretched without damage. Early correction of all the components of the deformity in the shortest possible time is necessary for the proper development of the foot, since plaster-cast treatment prolonged for many months interferes with growth and may cause stiffness of the joints.

Correction of a severe equinus deformity can be radically shortened by subcutaneous section of the heel cord followed by the application of a plaster cast (with the foot in maximum dorsiflexion) for three weeks. After this procedure, the tendon always heals with little scarring; and, if it is done early, a posterior capsulotomy of the ankle joint is unnecessary and rocker bottom and flattening of the upper articular surface of the talus are prevented. However, the heel cord should be sectioned only after the other components of the club-foot deformity are completely corrected. Of seventy-four feet with severe equinus deformity treated with a subcutaneous section of the heel cord in the primary treatment, only eight required further surgery to treat a recurrent equinus deformity. Only seven tendo achillis lengthening operations were performed in the entire series.

Recurrence of the heel varus deformity and adduction of the fore part of the foot are common even after complete correction. Denis Browne splints on shoes worn full time for the first two or three months after correction, and part

**Fig. 4** Above: Club foot in a ten-day-old male infant. Photographs made after removal of the plaster casts which had been applied three days previously. Cavus deformity is completely corrected on the right side and partially corrected on the left side. Five more plaster casts were applied in a period of three weeks. The child wore Denis Browne splints part time for four years. Below: At five years of age both feet were well corrected.



time thereafter until the child is from three to five years of age, are useful to prevent recurrences in many cases. However, only half of the recurrences could be blamed on the neglect of follow-up treatment; often these could be corrected by the reapplication of a few plaster casts. Some form of surgical treatment was necessary to prevent further recurrence in the more severe cases. A transfer of the anterior [3] or posterior [2] tibial tendons to the third cuneiform or to the cuboid in these feet seems to be the most effective procedure to prevent further recurrence of the heel varus deformity. The tendon transfer should be performed only after the foot is well corrected either by the application of several corrective plaster casts or, if necessary, by a medial release operation. However, the medial release operation often leaves extensive scarring and stiffness in the mid-tarsal joints and, when possible, should be avoided. Early transfer of the anterior tibial tendon in the very severe cases reduces greatly the need for this operation. It was performed in only three of our feet. The anterior tibial tendon was preferred over the posterior tibial for transfer because the operation is easier to perform and

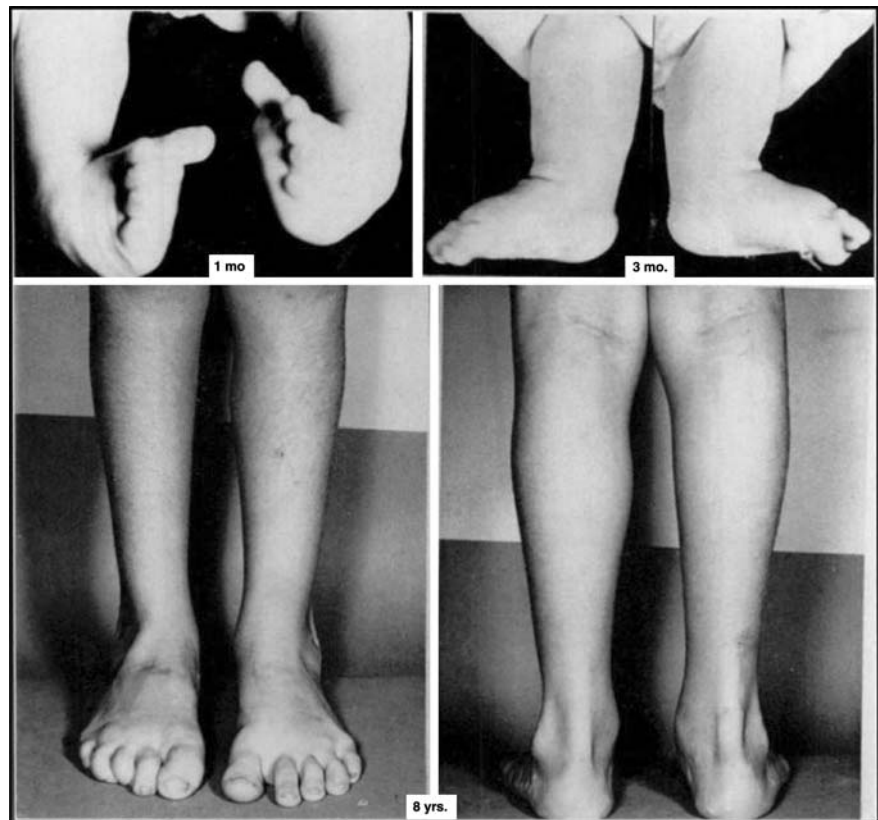
the anterior tibial functions in phase with the foot dorsiflexors, thereby making unnecessary postoperative training. Excessive plantar flexion on the first metatarsal and cock-up of the big toe was observed in only six of our feet; three of them before and three after anterior tibial transfer. This deformity was corrected by the transfer of the long extensor of the big toe to the neck of the first metatarsal. The nine failures of the anterior tibial transfer to correct permanently the varus deformity of the heel could be blamed on surgical errors.

Tibial osteotomy was not necessary in our patients because medial tibial torsion was corrected during the application of toe-to-groin plaster casts followed by the use of Denis Browne splints. Tibial torsion will remain uncorrected if below-the-knee plaster casts are inadvisably used in the treatment.

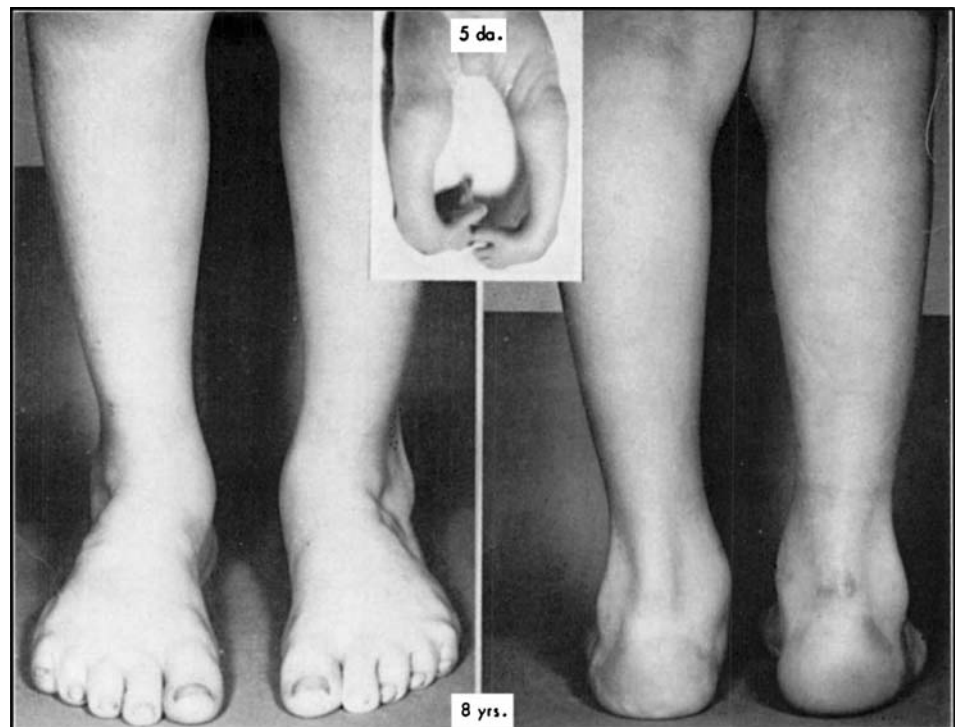
### Summary

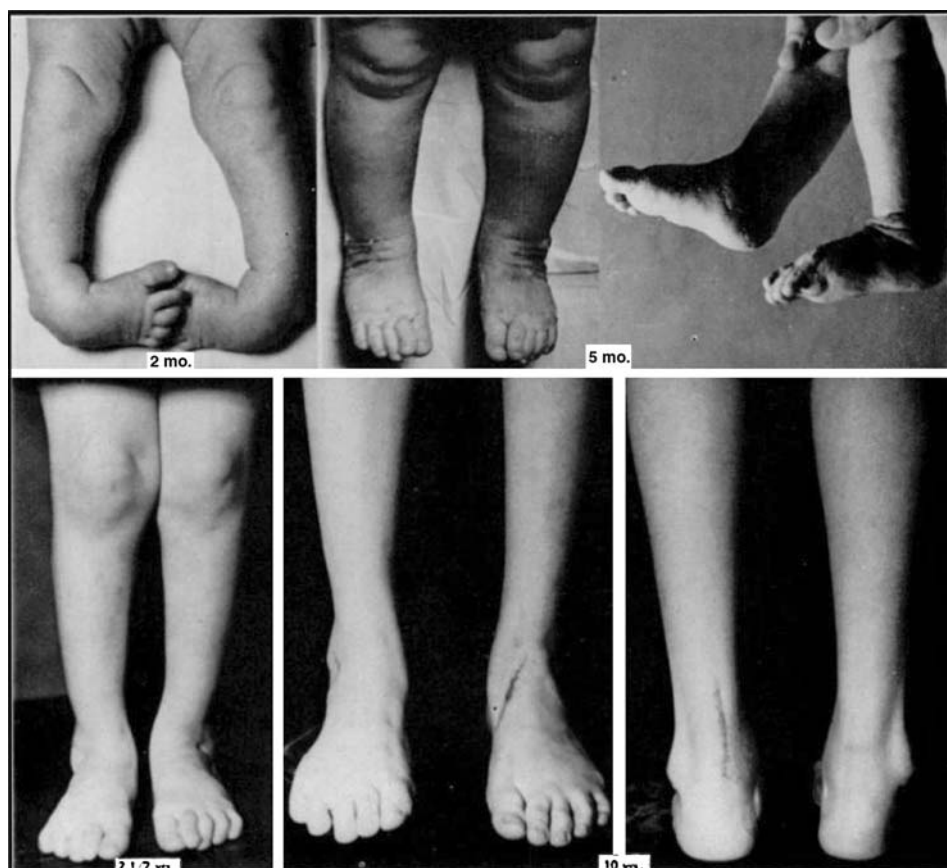
The results of treatment in sixty-seven patients with a total of ninety-four severe congenital club feet were evaluated

**Fig. 5** *Above, left:* Bilateral club-foot deformities in a one-month-old female infant. Six plaster casts were applied in a period of one month, followed by bilateral subcutaneous tendo achillis tenotomy. *Above, right:* At three months of age both feet were corrected. At fourteen months of age, the deformity recurred on the left and was treated by application of two toe-to-groin plaster casts. A bilateral recurrence of the deformity occurred when the child was five years old and was treated by transfer of the anterior tibial tendon to the third cuneiform after the application of three plaster casts. *Below:* At eight years of age, both feet remained well corrected.



**Fig. 6** Bilateral club-foot deformities in a five-day-old male infant treated with the application of ten plaster casts in a period of two months. A recurrence of the equinus deformity at one year of age was treated by the application of two toe-to-groin plaster casts and subcutaneous tenotomy. All the components of the club-foot deformity recurred at three years of age. Three plaster casts were then applied, followed by the transfer of the anterior tibial tendon to the third cuneiform. When the child was eight years old the left foot was well corrected. On the right a 20-degree metatarsus adductus and 10-degree heel varus deformity persisted.





**Fig. 7** Bilateral club-foot deformities in a female infant treated at two months with six plaster casts in a period of six weeks, followed by a bilateral subcutaneous tendo achillis tenotomy. Denis Browne splints on shoes were worn for four years. Photographs made when she was five months old, and later, when she was two and one-half years old, show all the components of the deformity well corrected. A mild recurrence of the deformity occurred when she was five years old, which was treated by the application of four plaster casts which were changed every ten

five to thirteen years after the initial treatment. The primary treatment consisted in the application of several plaster casts changed frequently for an average period of 9.5 weeks. In many instances a subcutaneous tendo achillis tenotomy was performed in the primary treatment to obtain a complete correction of the equinus deformity. Denis Browne splints were used in the follow-up care in all patients.

In fifty-three feet the deformity recurred and required further treatment. The recurrences of the equinus deformity were usually mild and responded to conservative treatment. Only seven tendo achillis lengthening operations were performed. A transfer of the anterior tibial tendon to the dorsolateral aspect of the foot was performed in thirty-nine feet to prevent further recurrences of the heel varus deformity. Medial release operations were necessary in only three feet. In no case was bone surgery performed.

days. Then, Denis Browne splints on the shoes were worn for three years. When she was nine years old the deformity recurred again. The left foot was treated by lengthening of the heel cord and transfer of the anterior tibial to the third cuneiform. *Below, right:* In the photographs made four months after operation, the deformity is well corrected on the left side. A 15-degree varus deformity of the heel and 5-degree equinus deformity persisted on the right. Subsequently, a lengthening of the heel cord and transfer of the anterior tibial tendon was done on the right foot.

The results in 71 per cent of the feet were good; in 28 per cent a slight residual deformity persisted; and in one foot a poor result was obtained.

## References

1. BROCKMAN, E. P.: Congenital Club-Foot (Talipes Equinovarus). Bristol, John Wright and Sons, Ltd., 1930.
2. FRIED, AMNON: Recurrent Congenital Club Foot. The Role of the M. Tibialis Posterior in Etiology and Treatment. *J. Bone and Joint Surg.*, **41-A**: 243-252, March 1959.
3. GARCEAU, G. J., and MANNING, K. R.: Transposition of the Anterior Tibial Tendon in the Treatment of Recurrent Congenital Club-Foot. *J. Bone and Joint Surg.*, **29**: 1044-1048, Oct. 1947.
4. HEYMAN, C. H.; HERNDON, C. H.; and STRONG, J. M.: Mobilization of the Tarsometatarsal and Intermetatarsal Joints for the Correction of Resistant Adduction of the Fore Part of the Foot in Congenital Club-Foot or Congenital Metatarsus Varus. *J. Bone and Joint Surg.*, **40-A**: 299-310, Apr. 1958.

5. CRONKITE, E. P.; BOND, V. P.; FLIEDNER, M.; and RUBINI, J. R.: The Use of Tritiated Thymidine in the Study of DNA Synthesis and Cell Turnover in Hematopoietic Tissues. *Lab. Invest.*, **8**: 263–277, 1959.
6. DUTHIE, R. B.: A Histochemical Study of Transplanted Skeletal Tissue During Tissue Culture *In Vivo*. *British J. Plast. Surg.*, **11**: 1–30, 1958.
7. DE BRUYN, P. P. H., and KABISCH, W. T.: Bone Formation by Fresh and Frozen Autogenous and Homogenous Transplants of Bone, Bone Marrow and Periosteum. *Am. J. Anat.*, **96**: 375–405, 1955.
8. FELL, H. B.: Skeletal Development in Tissue Culture. *In Biochemistry and Physiology of Bone*, Chapt. 14. Edited by Geoffrey H. Bourne. New York, Academic Press Inc., 1956.
9. GOLDHABER, PAUL: Osteogenic Induction Across Millipore Filters *In Vivo*. *Science*, **133**: 2065–2067, 1961.
10. GREULICH, R. C.; CAMERON, I. L.; and THRASHER, J. B.: Stimulation of Mitosis in Adult Mice by Administration of Thymidine. *Proc. Nat. Acad. Sciences*, **47**: 743–748, 1961.
11. HAM, A., and GORDON, S.: The Origin of Bone that Forms in Association with Cancellous Chips Transplanted into Muscle. *British J. Plast. Surg.*, **5**: 154–160, 1952.
12. HUGGINS, C. B.: The Formation of Bone under the Influence of Epithelium of the Urinary Tract. *Arch. Surg.*, **22**: 377–407, 1931.
13. HURLEY, L. A.; STINCHFIELD, F. E.; BASSETT, C. A. L.; and LYON, W. H.: The Role of Soft Tissues in Osteogenesis. *J. Bone and Joint Surg.*, **41-A**: 1243–1254. Oct. 1959.
14. JOFTES, D. L.: Liquid Emulsion Autoradiography with Tritium. *Lab. Invest.*, **8**: 131–136, 1959.
15. LOCROIX, PIERRE: Organizers and the Growth of Bone. *J. Bone and Joint Surg.*, **29**: 292–296, Apr. 1947.
16. LEVANDER, G.: A Study of Bone Regeneration. *Surg., Gynec., and Obstet.*, **67**: 705–714, 1938.
17. MOSS, M. L.: Extraction of an Osteogenic Inductor Factor from Bone. *Science*, **127**: 755, 1958.
18. OLLIER, L.: *Traité Experimental et Clinique de la Regeneration des Os*. Vol. I. Paris, Victor Masson et Fils, 1867.
19. PEER, L. A.: *Transplantation of Tissues*. Vol. I. Part II. Baltimore, The Williams and Wilkins Co., 1955.
20. RIGAL, W. M.: The Use of Tritiated Thymidine in Studies of Chondrogenesis. *In Radioisotopes and Bone (Symposium)*, pp. 197–225, edited by F. C. McLean, P. Lacroix, and A. M. Budy. Oxford, Blackwell Scientific Publications, 1962.
21. SABET, T. Y.; HIDVEGI, E. B.; and RAY, R. D.: Bone Immunology. II. Comparison of Embryonic Mouse Isografts and Homografts. *J. Bone and Joint Surg.*, **43-A**: 1007–1021, Oct. 1961.
22. TAYLOR, J. H.; WOODS, P. S.; and HUGHES, W. L.: The Organization and Duplication of Chromosomes as Revealed by Autoradiographic Studies Using Tritium Labeled Thymidine. *Proc. Nat. Acad. Sciences Sci.*, **43**: 122–127, 1957.
23. TONNA, E. A.: Periosteal Osteoclasts, Skeletal Development and Aging. *Nature*, **185**: 405–406, 1960.
24. VERNINO, D. M., and LASKIN, D. M.: Sex Chromatin in Mammalian Bone. *Science*, **132**: 675–676, 1960.
25. WOLFF, JULIUS: Zur Osteoplastik. *Berliner Klin. Wochenschr.*, **6**: 492–494, 1869.
26. WOODRUFF, M. F. A., and NISBET, N. W.: Transplantation of Bone. *In The Transplantation of Tissues and Organs* edited by M. F. A. Woodruff. Springfield, Illinois, Charles C. Thomas, 1960.
27. YOUNG, R. W.: Regional Differences in Cell Generation Time in Growing Rat Tibiae. *Exper. Cell. Res.*, **26**: 562–567, 1962.